

Clinical and Radiographic Results of Indirect Decompression and Posterior Cervical Fusion for Single-Level Cervical Radiculopathy Using an Expandable Implant with 2-Year Follow-Up

Kris Siemionow¹ Piotr Janusz^{1,2} Frank M. Phillips³ Jim A. Youssef⁴ Robert Isaacs⁵
Marcin Tyrakowski^{1,6} Bruce McCormack⁷

¹Department of Orthopaedic Surgery, University of Illinois, Chicago, Illinois, United States

²Spine Disorders and Pediatric Orthopedics Department, University of Medical Sciences, Poznan, Poland

³Rush University Medical Center, Minimally Invasive Spine Institute, Chicago, Illinois, United States

⁴Orthopaedic Surgery, Spine Colorado, Durango, Colorado, United States

⁵Department of Neurosurgery, Duke University, Durham, North Carolina, United States

⁶Department of Orthopaedics, Pediatric Orthopaedics and Traumatology, The Centre of Postgraduate Medical Education, Warsaw, Poland

⁷Department of Neurosurgery, University of California San Francisco Medical Center, San Francisco, California, United States

Address for correspondence Piotr Janusz, MD, Department of Orthopedic Surgery, University of Illinois at Chicago, 835 S. Wolcott, Chicago, IL 60612, United States (e-mail: mdpjanusz@gmail.com).

J Neurol Surg A 2016;77:482–488.

Abstract

Background Indirect posterior cervical nerve root decompression and fusion performed by placing bilateral posterior cervical cages in the facet joints from a posterior approach has been proposed as an option to treat select patients with cervical radiculopathy. The purpose of this study was to report 2-year clinical and radiologic results of this treatment method.

Methods Patients who failed nonsurgical management for single-level cervical radiculopathy were recruited. Surgical treatment involved a posterior approach with decortication of the lateral mass and facet joint at the treated level followed by placement of the DTRAX Expandable Cage (Providence Medical Technology, Lafayette, California, United States) into both facet joints. Iliac crest bone autograft was mixed with demineralized bone matrix and used in all cases. The Neck Disability Index (NDI), visual analog scale (VAS) for neck and arm pain, and SF-12 v.2 questionnaire were evaluated preoperatively and 2 years postoperatively. Segmental (treated level) and overall C2–C7 cervical lordosis, disk height, adjacent segment degeneration, and fusion were assessed on computed tomography scans and radiographs acquired preoperatively and 2 years postoperatively.

Results Overall, 53 of 60 enrolled patients were available at 2-year follow-up. There were 35 females and 18 males with a mean age of 53 years (range: 40–75 years). The

Keywords

- ▶ DTRAX Facet System
- ▶ posterior cervical fusion
- ▶ cervical radiculopathy
- ▶ cervical spondylosis
- ▶ minimally invasive surgery

received

June 9, 2015

accepted after revision

March 24, 2016

published online

June 8, 2016

© 2016 Georg Thieme Verlag KG
Stuttgart · New York

DOI <http://dx.doi.org/10.1055/s-0036-1584210>.
ISSN 2193-6315.

operated level was C3–C4 ($N = 3$), C4–C5 ($N = 6$), C5–C6 ($N = 36$), and C6–C7 ($N = 8$). The mean preoperative and 2-year scores were NDI: 32.3 versus 9.1 ($p < 0.0001$); VAS Neck Pain: 7.4 versus 2.6 ($p < 0.0001$); VAS Arm Pain: 7.4 versus 2.6 ($p < 0.0001$); SF-12 Physical Component Summary: 34.6 versus 43.6 ($p < 0.0001$), and SF-12 Mental Component Summary: 40.8 versus 51.4 ($p < 0.0001$). No significant changes in overall or segmental lordosis were noted after surgery. Radiographic fusion rate was 98.1%. There was no device failure, implant lucency, or surgical reinterventions.

Conclusions Indirect decompression and posterior cervical fusion using an expandable intervertebral cage may be an effective tissue-sparing option in select patients with single-level cervical radiculopathy.

Introduction

Most patients with cervical radiculopathy due to degenerative spondylosis who fail medical management are treated with an anterior cervical approach. The intervertebral disk is typically removed along with offending osteophytes, and reconstruction with a fusion or disk replacement is performed.^{1,2} Anterior cervical surgery has been reported to be an effective treatment; however, it is associated with distinct complications with both fusion and arthroplasty procedures.^{3–5} Posterior foraminotomy is an alternative surgical approach to patients with radiculopathy with lateral nerve root compression, absent spinal cord compression, and it avoids the need for fusion surgery. Posterior foraminotomy is typically indicated in patients with unilateral radiculopathy, absent significant neck pain, with relatively maintained cervical lordosis.^{1,6,7}

Indirect posterior cervical nerve root decompression with application of a uniquely designed cervical cage placed bilaterally in the facet joint with concomitant posterior arthrodesis has been proposed as a less disruptive alternative surgical treatment for single-level cervical radiculopathy due to spondylosis.⁸ DTRAX Expandable Cage (Providence Medical Technology, Walnut Creek, California, United States) utilizes an expandable cervical cage placed in the facet joint that can increase the surface area of the neural foramina to indirectly decompress the nerve root and promote fusion at the treated level. Good clinical and radiographic results at 1-year follow-up have been reported for the treatment of single-level cervical radiculopathy due to spondylosis without symptomatic central canal stenosis, kyphosis, or segmental instability.⁸

The aim of the study is to present 2-year clinical and radiographic results of treatment for single-level cervical radiculopathy using an intervertebral cervical cage employed via a tissue-sparing posterior approach.

Material and Methods

The study protocol of a prospective multicenter single-arm study was reviewed and approved by the local institutional review board. Approval was also obtained prior to enrollment.

Subjects and Surgical Technique

A prospective multicenter single-arm study was initiated in 2009.⁸ Three centers participated in the study. Patients gave consent and were enrolled consecutively from the investigators' standard patient population between 2009 and 2011 based on inclusion and exclusion criteria. Inclusion criteria were single or multilevel cervical spondylosis (documented on magnetic resonance imaging and/or computed tomography [CT]) with radicular symptoms referable to a single level that was confirmed by clinical neurologic examination, selective nerve root block, or electrophysiologic studies, and no improvement after 6 weeks of nonsurgical treatment (collar immobilization, epidural steroid injections, physical therapy, chiropractic management). Exclusion criteria were cervical spondylolisthesis of more than 3.5 mm; instability found on dynamic radiographs; myelopathy; cervical kyphosis; decreased bone mineral density (T score of -2.5 or less); scoliosis; pregnancy; systemic inflammatory, metabolic, or connective tissue disease; any metal allergies; prior fracture or fusion of the involved level; chronic infection; involvement in workers' compensation and/or litigation.

All of the enrolled patients underwent indirect decompression and posterior cervical fusion using a cervical intervertebral cage.⁹ The procedure was performed under general anesthesia with the patient prone and the head resting on a donut. The shoulders were strapped down with tape, and fluoroscopy was used to visualize the cervical spine. The neck, upper back, and iliac crest were prepped. Autogenous iliac crest bone graft was obtained using a small trephine (Bone Graft Harvesting System, Acumed, Hillsboro, Oregon, United States) through a 2-cm incision. Morselized bone was mixed with demineralized bone matrix in all cases. A Steinman pin was placed externally and lateral to the patient's neck and lined up with the intended facet using lateral fluoroscopy to establish a cranial-caudal incision site and trajectory to the spinal level.⁸ The incision was made 1.5 fingerbreadths off midline and extending down through the fascia. The ligamentum nuchae was identified to permit a slight medial to lateral trajectory to the joint. Blunt dissection was performed to expose to the intended facet and adjacent lateral mass, which could be directly visualized.

Under fluoroscopy, an access chisel was inserted through posterior cervical incisions into both facet joints at the symptomatic level. If the patient had unilateral radiculopathy,

the symptomatic side was done first. Lateral mass adjacent to the posterior facet was decorticated with a trephine decorticator. A guide tube was then placed to maintain facet distraction and serve as a working channel. The guide tube has radiologic features to ensure ideal implant positioning including a radiolucent eye and a ridge that should approximate the posterior facet margin on lateral fluoroscopy when in place. Facet end plates were decorticated with rasps, and the DTRAX implant was deployed and anchored into the facet (→Fig. 1). Iliac crest aspirate with demineralized bone matrix was inserted through the guide tube onto the posterior facet and adjacent decorticated lateral mass.

Clinical Evaluation

All of the enrolled patients completed the Neck Disability Index (NDI), SF-12 v.2 Health Survey forms, and visual analog scale (VAS) for neck and arm pain before the surgery and at each follow-up visit (2 weeks, 6 weeks, 3 months, 6 months, 12 months, and 24 months postoperatively).

All the adverse events (AEs) and serious adverse events (SAEs), as defined by Title 45 of the Code of Federal Regulations part 46 (45 CFR 46), were noted during the entire period of 2-year follow-up. Pain, neurologic, and function symptoms were considered complications when a patient's complaint for any of these symptoms resulted in an unscheduled visit or when a

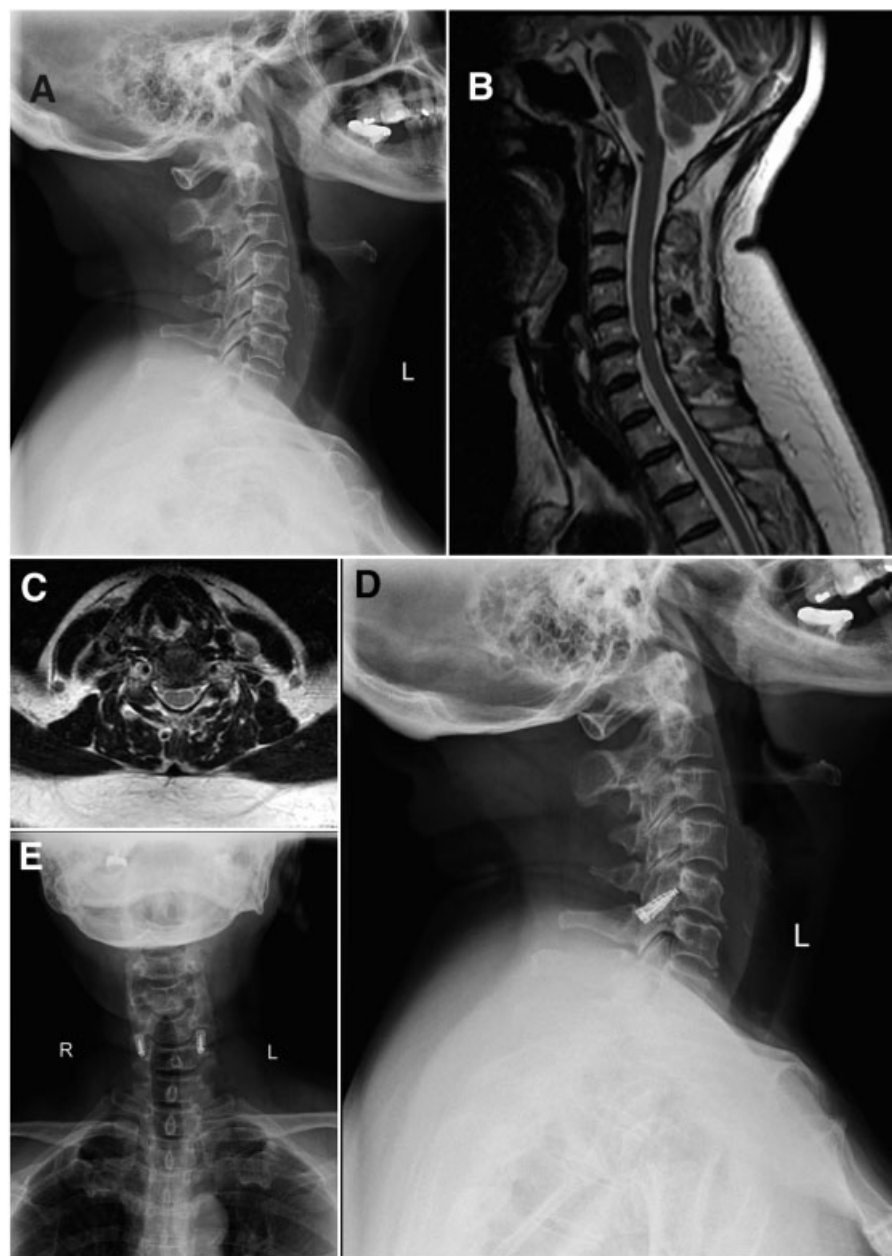


Fig. 1 (A) Lateral preoperative radiograph of a 56-year-old woman with upper extremity radiculopathy demonstrating C5–C6 intervertebral disk space degeneration. Cervical alignment is lordotic. (B) Sagittal preoperative magnetic resonance imaging (MRI) demonstrating C5–C6 intervertebral disk herniation without spinal cord compression. (C) Axial preoperative MRI demonstrating C5–C6 disk herniation with no spinal cord compression. (D) Two-year postoperative lateral radiograph demonstrating C5–C6 DTRAX Expandable Cage. No evidence of new adjacent segment degeneration. (E) Two-year postoperative anteroposterior radiograph demonstrating C5–C6 DTRAX Expandable Cage.

patient presented new or worsening pain, neurologic, and/or function symptoms as compared with the previous visit.

Radiographic Evaluation

All of the enrolled patients underwent standing radiographs of the cervical spine with anteroposterior and lateral views in neutral, flexion, and extension positions before the surgery and at regular intervals up until the 2-year follow-up. A cervical CT scan was obtained at 12 months in all patients. All of the available images were reviewed by two fellowship-trained orthopedic spine surgeons with 8 and 10 years of experience, respectively. Radiograph measurements were performed using Surgimap software (Surgimap Spine, New York, New York, United States) that has a built-in calibration tool. Surgimap allows for measurements of 0.1 degrees. For each measurement, the means from two reviewers were calculated and used for analysis.

The following quantitative parameters were assessed on the neutral lateral radiographs before the surgery and at 2-year follow-up: segmental lordosis at the treated level measured with the Cobb method¹⁰; overall cervical lordosis measured between the third (C3) and seventh (C7) cervical vertebrae using the Cobb method; and anterior, middle, and posterior disk height at the treated level defined as the shortest distance between the superior and the inferior end plates of the vertebral bodies at the treated level.

Fusion at the treated level at 2-year follow-up was assessed quantitatively on the lateral radiographs in flexion/extension views and was defined as a change in interspinous distance less than 2 mm; translational motion of less than 2 mm, and evidence of bridging trabecular bone between facets on CT scan at 12 months. CT scans were not performed at the 2-year follow-up.

The implant's qualitative evaluation on radiographs acquired at 2-year follow-up involved analysis for signs of implant failure, screw backout, device migration, or radiolucency around the implant.

Statistical Analysis

The data was analyzed using JMP statistical software v.10.0.2 (SAS Institute Inc., Cary, North Carolina, United States) and Microsoft Office Excel 2007 (Microsoft, Redmond, Washington, United States). Normal distribution of data was analyzed via the Shapiro-Wilk test. The paired *t* test or the Wilcoxon signed rank test was used to test the differences for the continuous data. An alpha level of 0.05 was considered significant.

Results

Sixty patients were initially enrolled into the study, and 53 of them (88%) were available at the 2-year follow-up. Of the seven patients who were not available for the 2-year follow-up, one died secondary to cardiac arrest during a cholecystectomy procedure. The remaining six patients had favorable 1-year results but were lost to follow-up. There were 35 females and 18 males remaining with a mean age at the time of surgery of 52.8 years (range: 40–75 years). The treated level

was C3–C4 in 3 patients (5.7%), C4–C5 in 6 (11.3%), C5–C6 in 36 (67.9%), and C6–C7 in 8 patients (15.1%). Bilateral treatment was achieved in 56 patients. The remaining four subjects had unilateral implant placement due to intraoperative facet fracture (two patients) and inability to access the facet (two patients). Mean operating time was 59.15 minutes (standard deviation [SD]: 19.98); mean estimated blood loss was 32.83 mL (SD: 16.68).

Clinical Evaluation

There was a significant decrease in the mean values of NDI and VAS for neck and arm pain as well as an increase in SF-12 v.2 physical and mental component scores at each follow-up out to 2 years compared with the preoperative values (►Table 1 and ►Fig. 2). Mean (SD) score for NDI decreased from 32.2 (6.2) at baseline to 8.1 (7.0) and 9.1 (7.7) at 12 and 24 months, respectively ($p < 0.001$). VAS score for neck pain improved from 7.5 (0.8) at baseline to 2.2 (2.2) and 2.6 (2.7) at 12 and 24 months. Similar improvements were observed for VAS arm pain: 7.4 (0.9) baseline, 2.3 (2.4) 12 months, and 2.6 (2.9) 24 months. SF-12 Physical Component Summary (PCS) showed significant improvement with mean (SD) score increasing from 34.3 (6.0) at baseline to 45.5 (8.6) and 43.7 (8.4) at 12 and 24 months. There were no significant differences in clinical outcomes between scores at the 12- and 24-month follow-up intervals (►Table 2).

All of the patients demonstrated improvement on their NDI when compared with their status preoperatively; this improvement was maintained at 2 years (►Table 2 and ►Fig. 2). Of the 53 patients, 2 patients had an increase in arm pain and 2 had an increase in neck and arm pain that was reflected in the VAS scores. Three patients had no change in neck pain, and one had no change in neck and arm pain scores for VAS.

The most common device-related AEs were shoulder pain and paresthesia, and the most common procedure-related AEs were postoperative pain, nausea, pain from the bone graft harvest site, and shoulder pain. Eight SAEs were reported. These included shoulder pain, shoulder/elbow weakness, bilateral sciatica, flank pain, midback pain, recurrence of neck pain, recurrence of arm pain, and acute exacerbation of osteoarthritis in the knee. Two additional SAEs were reported. One patient developed a postoperative thoracolumbar infection from a posterior fusion surgery prior to the cervical procedure. The infection was not related to the cervical implant and did not result in a cervical infection. One patient died from cardiac arrest during a routine cholecystectomy; this death was not related to the implant or the procedure.

Complications

No procedure- or device-related SAEs were noted during the 2-year follow-up. One patient reporting right shoulder pain was noted as a SAE; this event was reported as procedure related. There were no revision surgeries at the index level or at adjacent levels at the 2-year follow-up. Additionally, there were no device migrations, expulsions, or breakages at the 2-year follow-up.

Table 1 Clinical status of 53 patients treated with DTRAX Expandable Cage System recorded before surgery and at subsequent follow-up visits

Interval/Follow-up visit	Preoperative	10–14 d	6 wk	3 mo	6 mo	12 mo	24 mo
NDI							
Mean \pm SD, points	32.2 \pm 6.2	13.8 \pm 6.3	10.8 \pm 6.2	9.5 \pm 7.0	7.5 \pm 6.5	8.1 \pm 7.0	9.1 \pm 7.7
Change from baseline	–	–18.4	–21.4	–22.6	–24.7	–24.0	–23.1
VAS Neck Pain							
Mean \pm SD, cm	7.5 \pm 0.8	3.0 \pm 1.8	2.4 \pm 1.7	2.4 \pm 1.8	2.1 \pm 2.2	2.2 \pm 2.2	2.6 \pm 2.7
Change from baseline	–	–4.5	–5.1	–5.1	–5.4	–5.3	–4.9
VAS Arm Pain							
Mean \pm SD, cm	7.4 \pm 0.9	3.1 \pm 1.8	2.6 \pm 2.1	2.3 \pm 1.9	2.4 \pm 2.2	2.3 \pm 2.4	2.6 \pm 2.9
Change from baseline	–	–4.3	–4.8	–5.1	–5.0	–5.1	–4.8
SF-12 PCS							
Mean \pm SD	34.3 \pm 6.0	40.3 \pm 6.9	43.0 \pm 6.8	45.1 \pm 7.0	45.9 \pm 8.0	45.5 \pm 8.6	43.7 \pm 8.4
Change from baseline	–	+6.0	+8.6	+10.8	+11.6	+11.2	+9.2
SF-12 MCS							
Mean \pm SD	40.3 \pm 7.6	49.6 \pm 8.4	52.2 \pm 8.7	51.2 \pm 9.2	52.9 \pm 8.9	51.3 \pm 7.5	51.4 \pm 8.8
Change from baseline	–	+9.3	+11.9	+11.0	+12.6	+11.0	+11.2

Abbreviations: NDI, Neck Disability Index; SF-12 MCS, SF-12 v.2 Health Survey Mental Component Summary; SF-12 PCS, SF-12 v.2 Health Survey Physical Component Summary; VAS, Visual Analog Scale.

Radiographic Evaluation

The procedure did not alter overall cervical lordosis or segmental lordosis at the treated level (\rightarrow Table 3). There was a slight but statistically significant decrease in the posterior disk height at the treated level at 2-year follow-up.

The radiographic fusion rate, as defined by less than 2-mm change in interspinous distance measured on flexion exten-

sion radiographs taken at 24 months, was noted in 52 of 53 subjects (98.1%). Overall, the change in interspinous distance was 0.78 ± 0.58 mm with a range of 0.04 mm to 2.16 mm. Translational motion at the treated level of less than 2 mm was noted for all 53 subjects. There were no radiographic signs of implant loosening, breakage, migration, or screw backout. Evidence of bridging trabecular bone on CT scan was present in 93.3% of patients at 12 months.

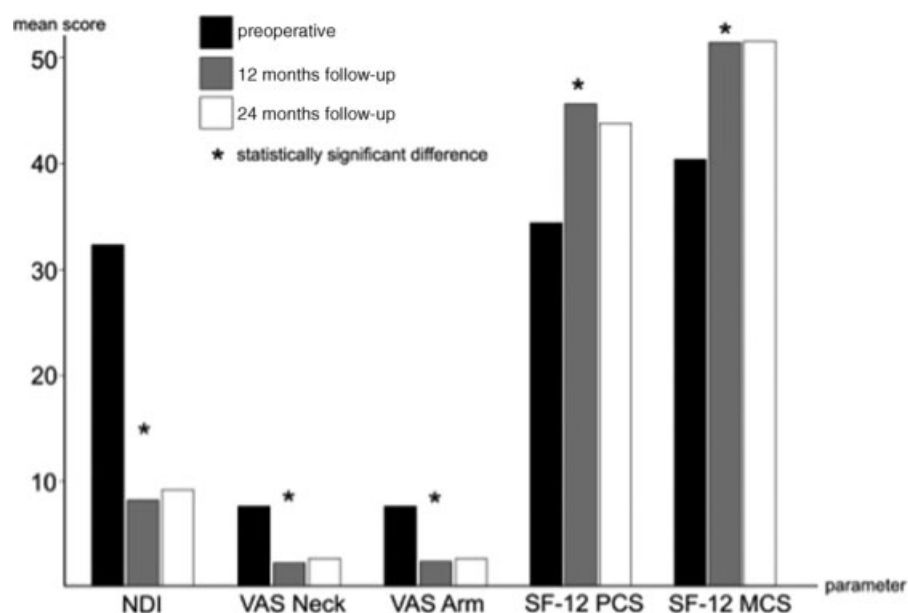


Fig. 2 Preoperative, 12-month, and 24-month clinical outcomes data. NDI, Neck Disability Index; VAS, Visual Analog Score; SF-12 MCS, Short Form 12 Health Survey Mental Component Summary; SF-12 PCS, Short Form 12 Health Survey Physical Component Summary.

Table 2 Comparison of 12- and 24-month clinical outcomes

Parameter	Preoperative vs. 12 mo		Preoperative vs. 24 mo		12 mo vs. 24 mo	
	Mean vs. mean	p value	Mean vs. mean	p value	Mean vs. mean	p value
NDI	32.2 vs. 8.1	$p < 0.0001^{aw}$	32.2 vs. 9.1	$p < 0.0001^{aw}$	8.1 vs. 9.1	$p = 0.2^w$
VAS Neck Pain	7.5 vs. 2.2	$p < 0.0001^{aw}$	7.5 vs. 2.6	$p < 0.0001^{aw}$	2.2 vs. 2.6	$p = 0.28^w$
VAS Arm Pain	7.4 vs. 2.3	$p < 0.0001^{aw}$	7.4 vs. 2.6	$p < 0.0001^{aw}$	2.3 vs. 2.6	$p = 0.27^w$
SF-12 PCS	34.3 vs. 45.5	$p < 0.0001^{aw}$	34.3 vs. 43.7	$p < 0.0001^{aw}$	45.5 vs. 43.7	$p = 0.05^t$
SF-12 MCS	40.3 vs. 51.3	$p < 0.0001^{at}$	40.3 vs. 51.4	$p < 0.0001^{at}$	51.3 vs. 51.4	$p = 0.93^t$

Abbreviations: NDI, Neck Disability Index; SF-12 MCS, SF-12 v.2 Health Survey Mental Component Summary; SF-12 PCS, SF-12 v.2 Health Survey Physical Component Summary; VAS, Visual Analog Scale; w, wilcoxon signed rank; t, t-test.

^aThe values are statistically significant.

Discussion

The study presents 2 years of clinical and radiographic outcomes in patients with single-level cervical radiculopathy who were treated with indirect posterior decompression and fusion using an expandable intervertebral cage. The implant is placed through a tissue-sparing posterior approach to the cervical spine and thus offers a less disruptive surgical option for single-level cervical radiculopathy due to spondylotic changes. For select patients, this approach may serve as an alternative to the more extensive anterior and/or posterior surgical procedures currently used.

Cervical facet distraction implants for indirect decompression for both radiculopathy and myelopathy were previously described by Goel and Shah.¹¹ The authors used an open approach to the posterior cervical spine followed by placement of metallic dowels to treat single-level and multilevel spondylotic disease. In this prospective analysis, excellent results were reported in 25 patients (70%) with a 6-month minimum follow-up. The current study supports good clinical and radiographic outcomes maintained at 2 years using a tissue-sparing cage system, thereby avoiding the morbidity of muscle dissection associated with posterior cervical approaches and direct foraminal decompression. Interestingly, outcomes were significantly improved within 2 weeks of the surgery suggesting rapid recovery and low morbidity related to the procedure.

Radiographic analysis at 2 years revealed a 98.1% fusion rate. This is comparable with fusion rates reported after anterior cervical discectomy and fusion (ACDF).¹² Clinical results suggest that the procedure was able to achieve indi-

rect neural decompression without the need for directly decompressing the involved nerve root. This concept is supported by a cadaveric study, in which Tan and colleagues demonstrated an average increase in the foraminal area of 18.4% after placement of an interfacet spacer.¹³ Leasure and Buckley reported that the rate of indirect foraminal effective distraction was maintained in flexed, extended, and axially rotated postures.¹⁴ Indirect foraminal decompression affords potential advantages, specifically eliminating any neural manipulation and risks of iatrogenic direct neural injury.

Although the procedure maintained overall (C2–C7) and segmental cervical lordosis at the index level, continued follow-up will be necessary to assess long-term lordosis. Important factors that have an impact on sagittal cervical alignment include the level implanted and the exact placement of the implant in relation to the central axis of rotation (COR). When taking the COR into consideration, the relationship between the posterior cervical cage and the COR is significantly different than that between a lumbar interspinous device and the lumbar COR, with the posterior cervical cage being closer to the cervical COR, potentially minimizing its effect on cervical sagittal alignment.^{15,16}

Today, most patients with single-level cervical radiculopathy due to degenerative spondylosis who fail medical management are treated with an ACDF or arthroplasty.^{17,18} This approach is associated with high fusion rates and good clinical outcomes. However, ACDF can be associated with dysphagia, dysphonia, and adjacent segment ossification from soft tissue disruption. Surgeons have also used posterior cervical foraminotomy successfully for the treatment of radiculopathy in

Table 3 Radiographic parameters measured preoperatively and at 24-month follow-up

Parameter	Preoperative	24 mo	Net change preoperative – 24 mo	p value
Overall cervical spine lordosis, degrees	14.7 ± 8.9	13.3 ± 8.3	– 1.4	$p = 0.40^t$
Segmental lordosis at treated level, degrees	2.4 ± 2.3	2.5 ± 2.4	+ 0.1	$p = 0.83^t$
Anterior disk height, mm	3.2 ± 1.2	2.8 ± 1.4	– 0.3	$p = 0.12^t$
Mid-disk height, mm	4.2 ± 1.1	4.0 ± 1.0	– 0.2	$p = 0.33^t$
Posterior disk height, mm	2.6 ± 0.9	2.1 ± 0.6	– 0.5	$p = 0.001^{at}$

^aIndicates statistically significant difference for the paired t test (†).

select cases.^{19,20} In select patients, cervical foraminotomy demonstrates outcomes similar to those reported for ACDF. Foraminotomy is typically indicated in patients with unilateral radiculopathy, absent significant neck pain, and maintained cervical lordosis.^{1,6,7} Foraminotomy can be associated with postoperative segmental instability and kyphosis at the index level secondary to overaggressive partial facet resection.²¹ In contrast, cervical fusion using bilateral posterior cages is an alternative treatment for patients with radiculopathy and neck pain, neutral or lordotic alignment, and unilateral or bilateral symptoms. It provides indirect foraminal decompression without the need for facet resection. In addition, the procedure has the potential to avoid dysphagia, dysphonia, and adjacent segment ossification. No single technique is perfect for all patients. For these reasons, the investigators studied posterior cervical fusion with DTRAX as an additional option to the previously mentioned procedures in patients with cervical radiculopathy.

This prospective study has its limitations. The study was designed to investigate the safety of indirect decompression and posterior cervical fusion with the DTRAX intervertebral cage as well as its clinical and radiographic efficacy. A randomized controlled study is necessary to demonstrate the comparative effectiveness of this novel technique. The use of an iliac crest bone graft adds an additional surgical site and contributes to a longer recovery. However, surgeons may choose to use alternative bone products. Although surgeons involved in this study have a consulting relationship with the study sponsor, pain and functional outcomes reported were completed by patients independent of the surgeons. Additionally, radiographic parameters were independently assessed.

Conclusions

This study addresses 2-year clinical and radiologic follow-up on patients presenting with single-level cervical radiculopathy treated with a tissue-sparing indirect posterior decompression and fusion procedure. The clinical and radiologic outcomes were similar to those reported at 1 year, supporting the durability of this approach for the management of single-level cervical radiculopathy. In select cases, this strategy should serve as an alternative to more invasive anterior and/or posterior surgical procedures utilized to treat cervical radiculopathy.

References

- 1 Fessler RC, Khoo LT. Minimally invasive cervical microendoscopic foraminotomy: an initial clinical experience. *Neurosurgery* 2002; 51(5, Suppl):S37-S45
- 2 Vieweg U. Anterior cervical discectomy and fusion. In: Vieweg U, ed. *Manual of Spine Surgery*. Berlin, Germany: Springer; 2012:127-133
- 3 Hilibrand AS, Robbins M. Adjacent segment degeneration and adjacent segment disease: the consequences of spinal fusion? *Spine J* 2004; 4(6, Suppl):190S-194S
- 4 Fountas KN, Kapsalaki EZ, Nikolakakos LG, et al. Anterior cervical discectomy and fusion associated complications. *Spine* 2007; 32(21):2310-2317
- 5 Riley LH III, Vaccaro AR, Dettori JR, Hashimoto R. Postoperative dysphagia in anterior cervical spine surgery. *Spine* 2010; 35(9, Suppl):S76-S85
- 6 Herkowitz HN, Kurz LT, Overholt DP. Surgical management of cervical soft disc herniation. A comparison between the anterior and posterior approach. *Spine* 1990;15(10): 1026-1030
- 7 Russell SM, Benjamin V. Posterior surgical approach to the cervical neural foramen for intervertebral disc disease. *Neurosurgery* 2004;54(3):662-665; discussion 665-666
- 8 McCormack BM, Bundoc RC, Ver MR, Ignacio JM, Berven SH, Eyster EF. Percutaneous posterior cervical fusion with the DTRAX Facet System for single-level radiculopathy: results in 60 patients. *J Neurosurg Spine* 2013;18(3):245-254
- 9 Siemionow K, McCormack BM, Menchetti PPM. Tissue sparing posterior cervical indirect decompression and fusion in foraminal stenosis. In: Menchetti P, ed. *Cervical Spine: Minimally Invasive and Open Surgery*. New York, NY: Springer Berlin Heidelberg; 2015:135-148
- 10 Cobb J. Outline for the study of scoliosis. *Am Acad Orthop Surg Instr Course Lect* 1948;5:261-275
- 11 Goel A, Shah A. Facetal distraction as treatment for single- and multilevel cervical spondylotic radiculopathy and myelopathy: a preliminary report. *J Neurosurg Spine* 2011;14(6): 689-696
- 12 Fraser JF, Härtl R. Anterior approaches to fusion of the cervical spine: a metaanalysis of fusion rates. *J Neurosurg Spine* 2007;6(4): 298-303
- 13 Tan LA, Gerard CS, Anderson PA, Traynelis VC. Effect of machined interfacet allograft spacers on cervical foraminal height and area. *J Neurosurg Spine* 2014;20(2):178-182
- 14 Leasure JM, Buckley J. Biomechanical evaluation of an interfacet joint decompression and stabilization system. *J Biomech Eng* 2014;136(7):
- 15 Patwardhan AG, Tzermiadianos MN, Tsitsopoulos PP, et al. Primary and coupled motions after cervical total disc replacement using a compressible six-degree-of-freedom prosthesis. *Eur Spine J* 2012; 21(Suppl (Suppl 5):S618-S629
- 16 Yue JJ. Primary indications and disc space preparation for cervical disc arthroplasty. In: Yue JJ, ed. *Motion Preservation Surgery of the Spine: Advanced Techniques and Controversies*. Philadelphia, PA: Saunders/Elsevier; 2008:185-192
- 17 Bhadra AK, Raman AS, Casey ATH, Crawford RJ. Single-level cervical radiculopathy: clinical outcome and cost-effectiveness of four techniques of anterior cervical discectomy and fusion and disc arthroplasty. *Eur Spine J* 2009;18(2):232-237
- 18 Sasso RC, Anderson PA, Riew KD, Heller JG. Results of cervical arthroplasty compared with anterior discectomy and fusion: four-year clinical outcomes in a prospective, randomized controlled trial. *J Bone Joint Surg Am* 2011;93(18): 1684-1692
- 19 Scoville WB, Whitcomb BB. Lateral rupture of cervical intervertebral disks. *Postgrad Med* 1966;39(2):174-180
- 20 Frykholm R. Cervical root compression resulting from disc degeneration and root sleeve fibrosis. *Acta Chir Scand* 1951; 160:1-149
- 21 Skovrlj B, Gologorsky Y, Haque R, Fessler RG, Qureshi SA. Complications, outcomes, and need for fusion after minimally invasive posterior cervical foraminotomy and microdiscectomy. *Spine J* 2014;14(10):2405-2411